

Original Studies

Rheolytic Thrombectomy and Platelet Glycoprotein IIb/IIIa Blockade for Stent Thrombosis

Stéphane Rinfret, MD, Donald E. Cutlip, MD, Peter T. Katsiyannis, MD, Kalon K.L. Ho, MD, David J. Cohen, MD, Joseph P. Carrozza, Jr., MD, and Roger J. Laham,* MD

Conventional transcatheter-based strategies result in good procedural success but poor clinical outcome in the treatment of intracoronary stent thrombosis. A combined approach of mechanical thrombus burden reduction using AngioJet rheolytic thrombectomy with adjunctive glycoprotein (GP) IIb/IIIa antagonists has not been studied. Between July 1998 and August 2000, 15 patients (17 procedures) underwent AngioJet thrombectomy for stent thrombosis at the Beth Israel Deaconess Medical Center. Patients were followed clinically through 6 months following the AngioJet procedure. All patients presented with signs of acute myocardial infarction at a median of 6 days following the original stenting procedure. Most vessels (88%) were occluded at presentation. A GP IIb/IIIa inhibitor was administered during 16 of the 17 procedures. Rheolytic thrombectomy resulted in complete removal of filling defects in all reviewed cases and led to significant improvement in lumen diameter and TIMI flow with reduction in the thrombotic lesion length (all *P* values < 0.05). Angiographic success (< 30% residual stenosis, TIMI 3 flow) was attained in all but one procedure. No patient required emergent coronary bypass grafting, repeat coronary angioplasty, or died in-hospital. At 6 months, there were no deaths and repeat revascularization was performed in four patients (29%). A combined approach of rheolytic thrombectomy with adjunctive GP IIb/IIIa blockade was highly effective in resolving stent thrombosis and was associated with favorable acute and long-term outcomes. *Cathet Cardiovasc Intervent* 2002;57:24–30.

© 2002 Wiley-Liss, Inc.

Key words: stent; thrombosis; thrombectomy; GP IIb/IIIa

INTRODUCTION

Optimal stent expansion and combined antiplatelet therapy with aspirin and adenosine diphosphate (ADP) receptor antagonists such as ticlopidine or clopidogrel have reduced the incidence of stent thrombosis to less than 1% in most recent studies [1–5]. However, the treatment of stent thrombosis remains a difficult task and is still associated with poor prognosis [5–11] despite early recanalization with catheter-based techniques such as balloon angioplasty or intracoronary urokinase [12]. Given the predominant role of platelets in stent thrombosis [13], reduction of the thrombus burden using mechanical approaches with adjunctive platelet glycoprotein (GP) IIb/IIIa inhibition may result in improved outcomes. This combined strategy had not been well studied; therefore, we present our single-center experience with AngioJet rheolytic thrombectomy with GP IIb/IIIa blockers in patients with stent thrombosis.

MATERIALS AND METHODS

Study Population

Between July 1998 and August 2000, 4,925 percutaneous coronary interventions were performed at the Beth Israel Deaconess Medical Center, and case-related information was entered prospectively into a database. This included 15 consecutive patients who underwent 17 AngioJet rheolytic thrombectomy procedures for stent

Cardiovascular Division, Beth Israel Deaconess Medical Center and Harvard Medical School, Boston, Massachusetts

*Correspondence to: Dr. Roger J. Laham, Cardiovascular Division, BIDMC/Harvard Medical School, 330 Brookline Avenue, Boston, MA 02215. E-mail: rlaham@caregroup.harvard.edu

Received 29 November 2001; Revision accepted 8 April 2002

DOI 10.1002/ccd.10275

Published online in Wiley InterScience (www.interscience.wiley.com).

thrombosis. Coronary angiography was performed urgently because of a high suspicion of that complication, i.e., stent placed within 60 days and ongoing signs of ischemia. Patients were selected for AngioJet thrombectomy procedure based on the angiographic appearance of the lesion. Only patients with target vessel diameter larger than 2 mm were considered for AngioJet thrombectomy, as clinically approved. Clinical, angiographic, and procedure-related information was obtained from online medical records, and cineangiograms were reviewed in all but one case.

Procedure Description

Rheolytic thrombectomy procedure was performed using the LF 140 AngioJet catheter (Possis Medical, Coon Rapids, MN) as previously described [14]. The catheter is attached to a driving unit which roller pump generates high-speed pulsed flow (50 ml/min) pushed into a high-pressure lumen. This lumen ends up in a 180° loop that separates into six high-pressure jets, directed retrograde into the collecting lumen of the catheter. The saline, which exits the loop at a speed of about 450 km/hr, creates a vortex (Venturi effect) that fragments and aspirates thrombus material.

The AngioJet 5 Fr catheter was first positioned distal to the suspected thrombosed stent. The pump unit was then activated and thrombectomy was performed by slow (0.5 mm/sec) withdrawal of the catheter. Several passes were performed until no improvement in angiographic appearance was noted. Following thrombectomy, the intervention was completed with balloon angioplasty and further coronary stenting when appropriate. Coronary slow-flow or no-reflow was treated with intracoronary (IC) diltiazem (250–500 µg) and/or nitroglycerin (100–200 µg).

Angiographic Evaluation

Quantitative cineangiography review was performed in 16 cases and was blinded to clinical data and angiographic outcomes. Procedural data and outcomes were later confirmed by review of online records. Antegrade flow was assessed according to the TIMI criteria [15], including frame counts [16]. Stent thrombosis was confirmed if a stent was placed in the past 60 days with one or both of the following criteria: total occlusion within the stent with or without intraluminal filling defects; filling defect (mobile, globular, “rat tail,” or sessile) or a convex curvature observed within or in the proximity of the lesion. Successful delivery of the AngioJet device was confirmed by careful review of the angioplasty report after completion of the angiographic analysis and was defined as positioning of the catheter beyond the presumed distal edge of the thrombotic lesion. Response to rheolytic thrombectomy was graded as previously

described (0, minimal or no change; 1, partial [$< 50\%$] removal of filling defect; 2, substantial [$> 50\%$] removal of filling defect; and 3, complete removal of filling defects) [14]. Post-AngioJet TIMI flow, frame count, and occurrence of distal embolization (new distal cutoff compatible with embolus, residual but displaced filling defects, or TIMI 0–1 flow in a distal branch nonresponsive to IC nitroglycerine or diltiazem) during the procedure were also evaluated. Slow-flow was diagnosed when a reduction in flow was noted without evidence of distal cutoff or dissection. Quantitative coronary angiography was performed as previously described [17]. Lesion length was measured shoulder to shoulder or to the end of the filling defect. Angiographic success was defined as residual stenosis of less than 30% by quantitative coronary angiography with TIMI 3 flow.

Clinical Evaluation and Long-Term Follow-Up

Data on hospital outcomes were collected prospectively and reviewed for occurrence of death, stroke, myocardial infarction (CK and CK-MB levels were routinely monitored for 24 hr after the procedure and a CK > 2 times the upper limit of normal with the MB fraction $> 5\%$ was considered diagnostic for a myocardial infarction), repeat revascularization, and recurrent ischemia. Clinical outcomes during follow-up were collected by careful review of the online record and by telephone contact. Target vessel ischemia was defined as any inducible and reversible ischemia in the territory supplied by the target vessel, as assessed by stress-imaging methods (nuclear scintigraphy, echocardiography) or any electrically abnormal exercise treadmill test. Target vessel restenosis was defined as any stenosis $\geq 50\%$ in the target vessel, including target vessel occlusion. The occurrence of death, recurrent MI, and target vessel revascularization was also gathered.

Statistical Analysis

Discrete data are reported as percentage, and continuous data as mean \pm standard deviation and median or range. One-sample Wilcoxon sign-rank tests were performed for comparison of pre- and postprocedure angiographic variables. All *P* values were two-tailed and a *P* value < 0.05 was considered statistically significant. All statistical analyses were performed with SAS for Windows, version 8 (SAS Institute, Cary, NC).

RESULTS

Clinical Baseline Characteristics

This case series consisted of 15 patients who underwent 17 rheolytic thrombectomy procedures for stent thrombosis. Baseline characteristics are presented in Ta-

TABLE I. Clinical Baseline Characteristics of the 15 Patients Treated With Rheolytic Thrombectomy for Stent Thrombosis (17 Procedures)*

Male gender	5/15 (33)
Age (years)	64 ± 10 [64]
Hypertension	12/15 (80)
Diabetes	6/15 (40)
Smoking (prior or current)	7/15 (47)
Prior MI (prior to current admission)	13/17 (76)
LV ejection fraction (in %)	46 ± 13 [53]
Original stenting procedure	
Under GP IIb/IIIa coverage	8/15 (53)
Total stent length implanted (mm)	29 ± 14 [25]
Final balloon diameter used (mm)	3.0 ± 0.4 [3.0]
Native coronary stenting	13/15 (87)
Vessel or graft target vessel	
LAD (%)	7/15 (47)
LCx (%)	2/15 (13)
RCA (%)	6/15 (40)
Stenting involving a bifurcation	4/15 (27)
At presentation with stent thrombosis	
Acute MI (ST-T segment elevation or prolonged chest pain with rising CK)	17/17 (100)
Delay from previous procedure (days)	20 ± 25 [6]
Within 1 week	9/17 (53)
Emergent procedure	16/17 (94)
Cardiogenic shock	1/17 (6)
Thrombolytics	1/17 (6)
GP IIb/IIIa antagonist	16/17 (100)

*Data are presented as mean ± SD [median] or number/total (%) of patients.

ble I. All 15 patients underwent the initial stent placement in the setting of an acute coronary syndrome, 71% presenting originally with an acute MI and 29% with unstable angina, and GP IIb/IIIa antagonists were administered in 53% of these procedures. Current-generation slotted-tube stents (MultiLink Duet and Tristar, NIR or Crown stents) were used in all but one patient (AVE GFX-II) and placed in a native coronary in 13 of these 15 patients, mostly in the left anterior descending artery (7/15). The total length of implanted stent was 28 ± 14 mm (range, 13–59 mm) and final balloon diameter was 3.0 ± 0.4 mm (range, 2.5–3.5 mm). High-pressure dilatation (≥ 12 atm; mean, 15 ± 3 atm) was performed in all patients. In four cases, stenting involved a bifurcation.

All patients presented with clinical evidence of ongoing myocardial infarction, with either ST-T segment elevation (16/17) or prolonged chest pain with rising CK in the remaining patient. Patients presented at a median of 6 days (range, 0–58 days) following stent implantation and were treated with AngioJet thrombectomy. Late stent thrombosis (58 days) was observed in a patient treated with brachytherapy during the initial stenting procedure. Stent thrombosis recurred in two patients (thus the 17 procedures). One patient received fibrinolytic therapy (Retevase) prior to angiography. All patients except one

TABLE II. Baseline Angiographic Characteristics, Procedures, and Acute Angiographic Outcomes (17 Procedures)

Baseline	
Initial vessel occlusion (TIMI 0)	15/17 (88)
Pre-AngioJet	
Reference diameter (mm)	2.7 ± 0.9 [2.6]
MLD (mm)	0.4 ± 0.4 [0.4]
Diameter stenosis (in %)	84 ± 16 [88]
Lesion length, including thrombus (mm)	17 ± 8 [15]
TIMI grade 0–1	10/16 (63)
TIMI frame count (of TIMI > 0)	64 ± 47 [50]
Procedure	
Successful delivery of AngioJet device (%)	16/17 (94)
Balloon inflation prior to thrombectomy (%)	3/17 (18)
New stent implantation (%)	4/17 (24)
Stent reexpansion (%)	7/17 (41)
Outcomes	
Immediately post-AngioJet	
Reference diameter (mm)	2.8 ± 0.7 [2.5]
MLD (mm)	1.9 ± 0.4 [1.9]
Diameter stenosis (in %)	31 ± 19 [35]
Lesion length, including thrombus (mm)	7 ± 6 [8]
TIMI grade 3	13/16 [88]
TIMI frame count	28 ± 12 [23]
Change from pre-AngioJet	
Reference diameter (mm)	−0.1 ± 0.4 [−0.1]
MLD (mm)	+1.4 ± 0.6 [1.4] ^a
Diameter stenosis (in %)	−53 ± 22 [−51] ^a
Lesion length, including thrombus (mm)	−11 ± 9 [−7] ^a
Drop in TIMI grade flow	0/17 (0)
TIMI frame count	−33 ± 41 [−15] ^a
Complete removal of filling defects	15/16 (94)
Distal embolization	3/17 (18)
Transient slow flow	5/17 (29)
Angiographic success (< 30% DS and TIMI 3)	16/17 (94)

*Data are presented as mean ± SD [median] or number/total (%) of patients. DS = diameter stenosis; MLD = minimal luminal diameter; TIMI = Thrombolysis in Myocardial Infarction.

^aOne-sample Wilcoxon sign-rank test $P < 0.05$.

received platelet GP IIb/IIIa antagonists (tirofiban in 41%, eptifibatide in 18%, and abciximab in 35% of patients). One patient presented in cardiogenic shock.

Baseline Angiographic Characteristics, Procedures, and Acute Angiographic Outcomes

Angiographic findings, procedures, and early outcomes are shown in Table II. The 5 Fr AngioJet catheter was successfully delivered in all but one case (bifurcation stenting). AngioJet thrombectomy was highly effective with an increase of 1.4 ± 0.6 mm in MLD ($P < 0.001$), resulting in a reduction of 53% ± 22% in lesion severity ($P < 0.001$). Following thrombectomy, TIMI grade 3 flow was achieved in 88% of cases (Fig. 1), with significant reduction in TIMI frame counts ($P = 0.02$). Complete removal of filling defects was observed in all reviewed cases (Fig. 2). Distal embolization occurred in three cases.

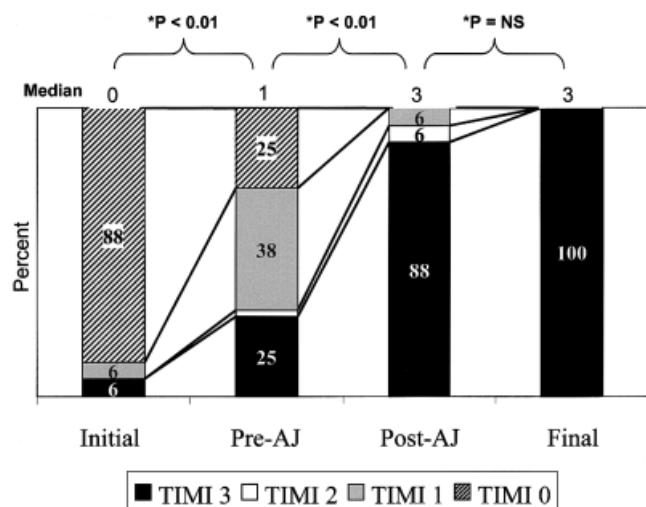


Fig. 1. Coronary flow following initial angiography, pre- and postthrombolytic thrombectomy and on final angiography. AJ = AngioJet. Asterisk: Wilcoxon sign-rank test.

Additional stenting was required in four cases. In seven cases, stent reexpansion was achieved with either higher pressure (three cases) or larger balloon (four cases). Transient no-reflow was observed in five cases and was successfully managed with IC diltiazem and/or nitroglycerin. Angiographic success, defined as less than 30% residual stenosis with TIMI 3 flow, was attained in 16/17 cases.

Acute and Long-Term Clinical Outcome

Clinical outcomes are shown in Table III. Stent thrombosis resulted in myocardial infarction (total CK > 2 times the upper limit of normal, with MB fraction \geq 5%) in all but one case, with a peak CK of $1,718 \pm 1,600$ mmol/l (range, 422–6,495 mmol/L). No patient required in-hospital repeat PTCA or bypass surgery, and there were no deaths.

Six-month clinical follow-up was obtained in all but one patient (14/15 patients) and is summarized in Table III. In the only unsuccessful case (a degenerated saphenous graft), the vessel was found subsequently occluded on follow-up angiography. Two patients presented with recurrent stent thrombosis involving the same vessel. The first patient, a 59-year-old female with a lupus anticoagulant, presented 8 days following the first stent thrombosis with a thrombotic occlusion of the same vessel (RCA), again successfully treated with AngioJet thrombectomy. She eventually underwent coronary bypass surgery after presenting with reocclusion 20 days after the second thrombectomy procedure. The second patient presented with a second stent thrombosis 6 days after the first episode, once more successfully treated with AngioJet thrombectomy. This patient was symptom-free 6

months after the second stent thrombosis. At 6 months, there were no deaths and repeat revascularization was performed in four patients (29%), but target vessel ischemia or restenosis was documented in 50%.

DISCUSSION

Although the incidence of stent thrombosis has declined to 0.5%–1.0% with current stent design, deployment strategies, and antiplatelet regimens, this sobering complication remains a difficult task to treat acutely and is still associated with a high rate of myocardial infarction and death in most recent series [5–12]. Indeed, the presence of angiographic thrombus results in increased complications with conventional percutaneous strategies [18–21] despite adjunctive stenting and GP IIb/IIIa use [22]. Clinical outcomes following stent thrombosis treatment with either balloon angioplasty or intravascular thrombolytics have resulted in adverse short-term outcomes despite acceptable flow restoration [12]. This finding may be due to the presence of residual thrombus resulting in further embolization and infarct extension. Thrombus removal may reduce the risk of embolization. Considering the prominent role of platelet in stent thrombosis [13], a combined approach of mechanical thrombus burden reduction with potent antiplatelet therapy may optimize therapy and outcomes.

This case series is the first with detailed clinical and angiographic analysis of the use of AngioJet thrombectomy for stent thrombosis in a nonselected population with the adjunctive use of GP IIb/IIIa inhibitors. Our study population presented known risk factors for stent thrombosis, namely, acute coronary syndromes, relatively small vessel size, and long stented segments [5,23]. Although we did not measure the time to set up the AngioJet catheter system in this series, it is usually performed in less than 5 min in our experience. Rheolytic thrombectomy in this setting was highly effective, resulting in restoration of TIMI 3 flow in all but one case and complete removal of filling defects. This process was accompanied with significant MLD enlargement and thrombotic lesion length reduction, surrogate endpoints for thrombus burden decrease. No-reflow was observed in close to one third of cases, but was successfully reversed in most cases with IC diltiazem or nitroglycerin. Distal embolization occurred in three cases without major impact on the clinical outcomes. No patient required emergent coronary bypass surgery or repeat PTCA.

Our data contrast strikingly with expected outcomes following traditional transcatheter therapy for stent thrombosis. Hasdai et al. [12] reported poor short-term outcomes following thrombolysis, angioplasty, or combined therapy in 23 patients treated for stent thrombosis. Although normal flow was achieved in 21 of 23 patients,

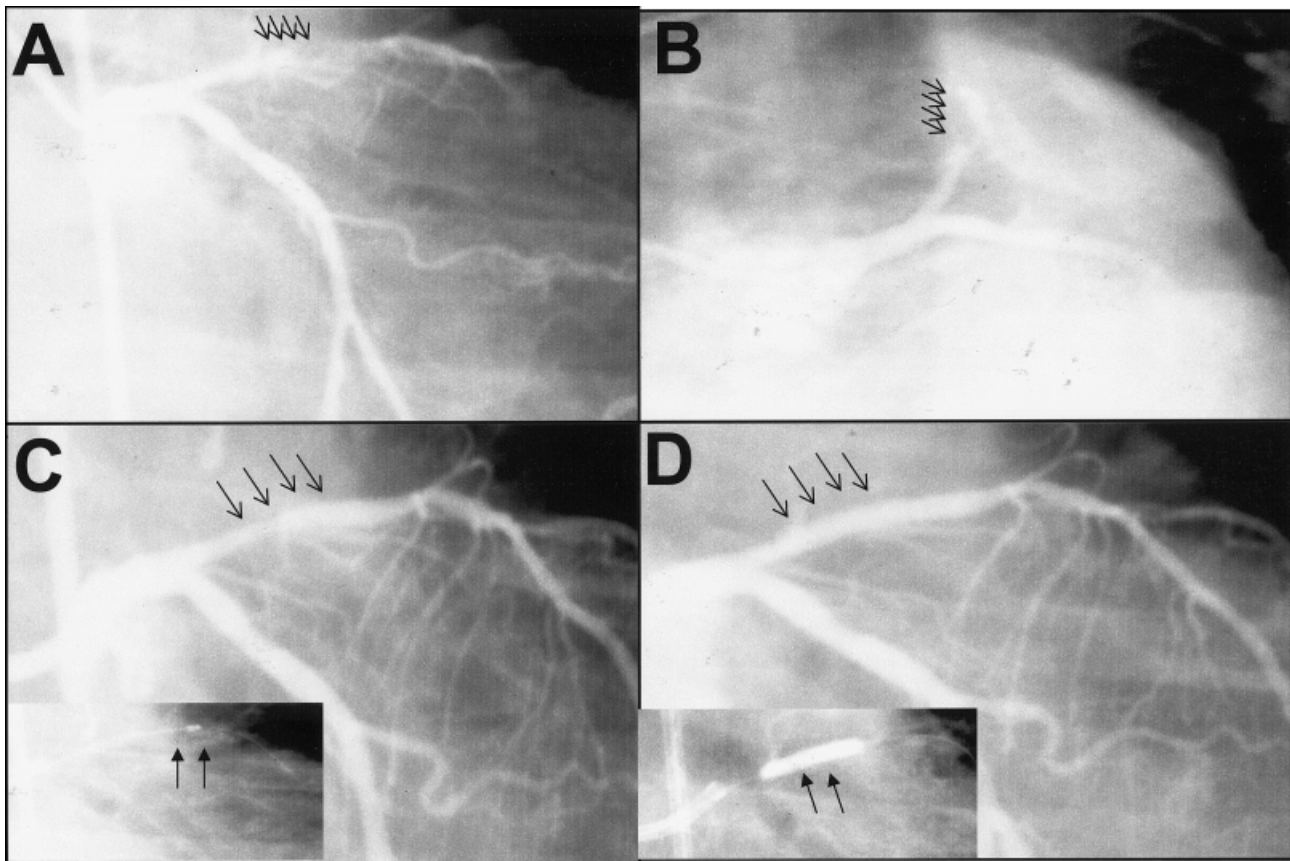


Fig. 2. Coronary angiography of a 75-year-old female with subacute thrombosis of a 2.5 × 23 mm stent placed in the proximal LAD. **A:** Subocclusion (TIMI 1) of the LAD with intraluminal filling defects (arrows) compatible with thrombus (right anterior oblique-caudal view). **B:** Same (left anterior oblique-

caudal view). **C:** AngioJet catheter positioned distal to the thrombosed stent (insert) with complete removal of filling defects (arrows) and restoration of normal antegrade flow. **D:** Stent reexpansion using a 3.0 mm noncompliant balloon inflated to 14 atm (insert) with final angiographic result (arrows).

9 patients required bypass surgery because of residual intracoronary thrombus and 2 patients with normal flow restoration died in-hospital. None of our 15 patients (17 cases) died in-hospital or during follow-up, despite a high rate of confirmed myocardial infarction. Although our sample is relatively small, this low mortality rate contrasts markedly with those reported in most earlier and recent studies, ranging from 8.9% to 20% [5–12]. This may be attributable to improved myocardial salvage with thrombus removal, possibly due to protection from distal embolization and infarct extension. However, distal embolization still occurred in 3 of these 17 cases. Whether this complication would have occurred more frequently without the use of rheolytic thrombectomy in these patients is unknown.

Despite favorable acute results, we observed a 50% incidence of target vessel restenosis or ischemia, which was higher than the incidence of restenosis following native coronary AngioJet reported by Nakagawa et al. [24]. Although the risk of restenosis following successful

TABLE III. Short- and Long-Term Clinical Outcomes Following Successful Rheolytic Thrombectomy for Stent Thrombosis (14 Patients, 16 Procedures)*

In-hospital	
Peak CK (mmol/l)	1,718 ± 1,600 [1,172]
Segmental left ventricular dysfunction	10/11 (91)
Post-event left ventricular EF (in %)	38 ± 12 [33]
Loss in EF (in %)	-8 ± 12 [-3] ^a
Repeat PCI	0/16 (0)
CABG	0/16 (0)
6-month	
Death	0/14 (0)
Recurrent MI	3/14 (21)
Target vessel repeat revascularization	4/14 (29)
CABG	1/14 (7)
PCI	4/14 (29)
Target vessel ischemia or restenosis	7/14 (50)
Combined incidence of death, MI, repeat revascularization	4/14 (29)

*Data are presented as mean ± SD [median] and number/total (%) of patients. CABG = coronary artery bypass surgery; EF = ejection fraction; MI = myocardial infarction; PCI = percutaneous coronary intervention.

^aWilcoxon sign-rank test. *P* value = 0.09.

stent thrombosis recanalization is unknown, factors leading to stent thrombosis might still play an adverse role against long-term patency.

There are several limitations to our study. First, the absence of control arm leads to historical comparisons to evaluate the incremental benefit of the adopted strategy. We did not review other stent thrombosis cases not managed with AngioJet for comparison. While the AngioJet was used only in > 2 mm vessel, there might be other factors leading to the decision to use this device or not (overall thrombus burden, operator experience, patient stability, cost consideration in situation where a simpler strategy of balloon angioplasty was felt to be appropriate). Nevertheless, our angiographic outcomes appear relatively similar to those reported with AngioJet thrombectomy outside the stent thrombosis setting [24,25] and compare favorably with alternate strategies [5–12]. Favorable outcomes have also been reported with the use of abciximab therapy in conjunction with balloon angioplasty in patients presenting with stent thrombosis, with TIMI 3 flow achieved in 8/10 patients with no in-hospital death [26]. Although we clearly observed acute angiographic benefits from mechanical thrombectomy, the incremental benefit of rheolytic thrombectomy over GP IIb/IIIa blockade alone was not assessed in this case series. It is unlikely that case selection for AngioJet therapy played in favor of our cohort, since they presented with very high-risk angiographic features. Nonetheless, these patients were clinically stable enough to survive up to the initial angiography and to allow extra few minutes to prepare the AngioJet system. Second, angiographic follow-up was not available on most patients and thus we used repeat revascularization and target vessel ischemia as surrogates for restenosis. Third, we did not measure thrombus area but rather the thrombotic lesion length and the MLD pre- and postintervention as an indicator of efficacy. Since the AngioJet catheter is unlikely to remove nonthrombotic material, any change from pre-AngioJet was likely the result of thrombus burden reduction. Fourth, close to 50% of these stent thrombosis episodes occurred more than 1 week after the original stenting procedure, an unusual finding in the current era of routine use of thienopyridine and aspirin as adjuvant antiplatelet therapy for coronary stenting [23]. Therefore, there might have been cases of occlusive restenosis complicated with local thrombosis. However, all cases presented in this series were angiographically documented episodes of acute coronary occlusion within a stented segment, with findings compatible with the presence of thrombus, in patients presenting with an acute myocardial infarction following a recent stenting procedure. Again, the favorable response in the majority of patients to AngioJet, a device that does not remove plaque or neointimal proliferation but only thrombus,

favors real stent thrombosis cases despite late presentation in some. Finally, despite very effective thrombus removal with this catheter system, it is likely that some thrombus fragment will escape from being sucked out though the tip of the catheter. The catheter was first delivered distal to the lesion before activation of the unit. Then, the driving unit was activated and the catheter withdrawn slowly. We felt this technique would minimize distal embolization, since the thrombus fragments would embolize toward the catheter tip and then be removed. However, distal embolization might occur as the catheter is passed through the thrombus-containing lesion prior to activation of the unit, especially in relatively small (< 3.0 mm) native coronary vessel. Whether the unit should be activated or not when the catheter is first advanced through the thrombosed segment deserves further evaluation.

In conclusion, rheolytic thrombectomy with the AngioJet, with adjunctive GP IIb/IIIa inhibition, results in significant reduction of thrombus burden and restoration of normal coronary flow in patients with stent thrombosis. Despite relatively large infarcted territories resulting in depressed ejection fraction in most, none of these patients died or required coronary bypass surgery in-hospital. Intermediate-term outcomes were favorable, with no deaths. AngioJet thrombectomy should then be considered in patients presenting with stent thrombosis in a target vessel larger than 2 mm in diameter. Further investigations are needed to evaluate the incremental benefits of adjunctive rheolytic thrombectomy over a less expensive strategy with initial balloon angioplasty without thrombus removal in stent thrombosis patients treated with GP IIb/IIIa agents.

ACKNOWLEDGMENTS

Supported in part by the Detweiler Fellowship Grant from the Royal College of Physicians and Surgeons of Canada (to S.R.), the Samuel McLaughlin Foundation (to S.R.), NIH grants MO1-RR01032 and HL 63609 (to R.J.L.).

REFERENCES

1. Colombo A, Hall P, Nakamura S, Almagor Y, Maiello L, Martini G, Gaglione A, Goldberg SL, Tobis JM. Intracoronary stenting without anticoagulation accomplished with intravascular ultrasound guidance. *Circulation* 1995;91:1676–1688.
2. Schomig A, Neumann FJ, Kastrati A, Schuhlen H, Blasini R, Hadamitzky M, Walter H, Zitzmann-Roth EM, Richardt G, Alt E, Schmitt C, Ulm K. A randomized comparison of antiplatelet and anticoagulant therapy after the placement of coronary-artery stents. *N Engl J Med* 1996;334:1084–1089.

3. Leon MB, Baim DS, Popma JJ, Gordon PC, Cutlip DE, Ho KK, Giambartolomei A, Diver DJ, Lasorda DM, Williams DO, Pocock SJ, Kuntz RE. Stent Anticoagulation Restenosis Study investigators. A clinical trial comparing three antithrombotic-drug regimens after coronary-artery stenting. *N Engl J Med* 1998;339:1665–1671.
4. Grines CL, Cox DA, Stone GW, Garcia E, Mattos LA, Giambartolomei A, Brodie BR, Madonna O, Eijgelshoven M, Lansky AJ, O'Neill WW, Morice MC. Stent Primary Angioplasty in Myocardial Infarction Study Group. Coronary angioplasty with or without stent implantation for acute myocardial infarction. *N Engl J Med* 1999;341:1949–1956.
5. Cutlip DE, Baim DS, Ho KK, Popma JJ, Lansky AJ, Cohen DJ, Carrozza JP, Chauhan MS, Rodriguez O, Kuntz RE. Stent thrombosis in the modern era: a pooled analysis of multicenter coronary stent clinical trials. *Circulation* 2001;103:1967–1971.
6. Serruys PW, Strauss BH, Beatt KJ, Bertrand ME, Puel J, Rickards AF, Meier B, Goy JJ, Vogt P, Kappenberger L, et al. Angiographic follow-up after placement of a self-expanding coronary-artery stent. *N Engl J Med* 1991;324:13–17.
7. Haude M, Erbel R, Issa H, Straub U, Rupprecht HJ, Treese N, Meyer J. Subacute thrombotic complications after intracoronary implantation of Palmaz-Schatz stents. *Am Heart J* 1993;126:15–22.
8. George BS, Voorhees WD, Roubin GS, Fearnot NE, Pinkerton CA, Raizner AE, King SB, Holmes DR, Topol EJ, Kereiakes DJ, et al. Multicenter investigation of coronary stenting to treat acute or threatened closure after percutaneous transluminal coronary angioplasty: clinical and angiographic outcomes. *J Am Coll Cardiol* 1993;22:135–143.
9. Foley JB, Brown RI, Penn IM. Thrombosis and restenosis after stenting in failed angioplasty: comparison with elective stenting. *Am Heart J* 1994;128:12–20.
10. Karrison GJ, Morice MC, Benveniste E, Bunouf P, Aubry P, Cattan S, Chevalier B, Commeau P, Cribier A, Eiferman C, Grollier G, Guerin Y, Henry M, Lefevre T, Livarek B, Louvard Y, Marco J, Makowski S, Monassier JP, Pernes JM, Rioux P, Spaulding C, Zemour G. Intracoronary stent implantation without ultrasound guidance and with replacement of conventional anticoagulation by antiplatelet therapy: 30-day clinical outcome of the French multicenter registry. *Circulation* 1996;94:1519–1527.
11. Moussa I, Di Mario C, Reimers B, Akiyama T, Tobis J, Colombo A. Subacute stent thrombosis in the era of intravascular ultrasound-guided coronary stenting without anticoagulation: frequency, predictors and clinical outcome. *J Am Coll Cardiol* 1997;29:6–12.
12. Hasdai D, Garratt KN, Holmes DR, Berger PB, Schwartz RS, Bell MR. Coronary angioplasty and intracoronary thrombolysis are of limited efficacy in resolving early intracoronary stent thrombosis. *J Am Coll Cardiol* 1996;28:361–367.
13. Jeong MH, Owen WG, Staab ME, Srivatsa SS, Sangiorgi G, Stewart M, Holmes DR, Schwartz RS. Porcine model of stent thrombosis: platelets are the primary component of acute stent closure. *Cathet Cardiovasc Diagn* 1996;38:38–43.
14. Whisenant BK, Baim DS, Kuntz RE, Garcia LA, Ramee SR, Carrozza JP. Rheolytic thrombectomy with the Possis Angiojet: technical considerations and initial clinical experience. *J Invas Cardiol* 1999;11:421–426.
15. Sheehan FH, Braunwald E, Canner P, Dodge HT, Gore J, Van Natta P, Passamani ER, Williams DO, Zaret B. The effect of intravenous thrombolytic therapy on left ventricular function: a report on tissue-type plasminogen activator and streptokinase from the Thrombolysis in Myocardial Infarction (TIMI Phase I) trial. *Circulation* 1987;75:817–829.
16. Gibson CM, Cannon CP, Daley WL, Dodge JT, Alexander B, Marble SJ, McCabe CH, Raymond L, Fortin T, Poole WK, Braunwald E. TIMI frame count: a quantitative method of assessing coronary artery flow. *Circulation* 1996;93:879–888.
17. Kuntz RE, Safian RD, Carrozza JP, Fishman RF, Mansour M, Baim DS. The importance of acute luminal diameter in determining restenosis after coronary atherectomy or stenting. *Circulation* 1992;86:1827–1835.
18. Mabin TA, Holmes DR Jr, Smith HC, Vlietstra RE, Bove AA, Reeder GS, Chesebro JH, Bresnahan JF, Orszulak TA. Intracoronary thrombus: role in coronary occlusion complicating percutaneous transluminal coronary angioplasty. *J Am Coll Cardiol* 1985;5:198–202.
19. Sugrue DD, Holmes DR Jr, Smith HC, Reeder GS, Lane GE, Vlietstra RE, Bresnahan JF, Hammes LN, Piehler JM. Coronary artery thrombus as a risk factor for acute vessel occlusion during percutaneous transluminal coronary angioplasty: improving results. *Br Heart J* 1986;56:62–66.
20. Deligonul U, Gabliani GI, Caralis DG, Kern MJ, Vandormael MG. Percutaneous transluminal coronary angioplasty in patients with intracoronary thrombus. *Am J Cardiol* 1988;62:474–476.
21. Ellis SG, Roubin GS, King SB, Douglas JS Jr, Weintraub WS, Thomas RG, Cox WR. Angiographic and clinical predictors of acute closure after native vessel coronary angioplasty. *Circulation* 1988;77:372–379.
22. Ellis SG, Guetta V, Miller D, Whitlow PL, Topol EJ. Relation between lesion characteristics and risk with percutaneous intervention in the stent and glycoprotein IIb/IIIa era: an analysis of results from 10,907 lesions and proposal for new classification scheme. *Circulation* 1999;100:1971–1976.
23. Cutlip DE. Stent thrombosis: historical perspectives and current trends. *J Thromb Thrombolysis* 2000;10:89–101.
24. Nakagawa Y, Matsuo S, Kimura T, Yokoi H, Tamura T, Hamasaki N, Nosaka H, Nobuyoshi M. Thrombectomy with AngioJet catheter in native coronary arteries for patients with acute or recent myocardial infarction. *Am J Cardiol* 1999;83:994–999.
25. Silva JA, Ramee SR, Cohen DJ, Carrozza JP, Popma JJ, Lansky AA, Dandreo K, Baim DS, George BS, McCormick DJ, Setum CM, Kuntz RE. Rheolytic thrombectomy during percutaneous revascularization for acute myocardial infarction: experience with the AngioJet catheter. *Am Heart J* 2001;141:353–359.
26. Casserly IP, Hasdai D, Berger PB, Holmes DR Jr, Schwartz RS, Bell MR. Usefulness of abciximab for treatment of early coronary artery stent thrombosis. *Am J Cardiol* 1998;82:981–985.